

ENDOVASCULAR TREATMENT OF COMPLETE INTERRUPTION OF THORACIC AORTA POST SURGICAL REPAIR OF AORTIC COARCTATION

Percutaneous treatment of atretic segment by radiofrequency perforation and PTFE covered Stent angioplasty

***Granja Miguel*., Trentacoste Luis*., Damsky Barbosa
Jesus*., Lucini Victorio*., Grinfeld Liliana**.***

Servicio de Hemodinamia y Cardiología Intervencionista

Hospital Italiano. Buenos Aires. ARGENTINA.

** Interventional Cardiology in Congenital Heart disease.*

*** Director.*

ENDOVASCULAR TREATMENT OF COMPLETE INTERRUPTION OF THORACIC AORTA POST SURGICAL REPAIR OF AORTIC COARCTATION

Patient: E.A. **Sex:** Male **Age:** 18 y.o.

History: At 8 y.o. was operated of Typical severe Aortic Coarctation. Left thoracotomy and subclavian flap aortoplasty technique was performed. A few days later, clinical signs of recoarctation were noted. No reoperation was proposed, and the patient was discharged, with antihypertensive medication.

Ten years after surgery , patient presented severe hypertension no responsive to medication and was referred to our Hospital.

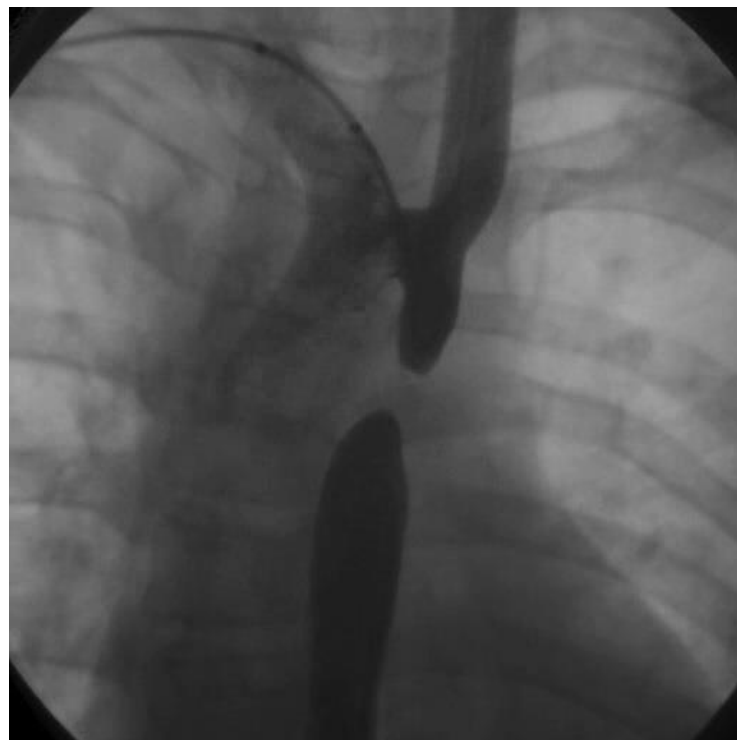ENDOVASCULAR TREATMENT OF COMPLETE INTERRUPTION OF THORACIC AORTA POST SURGICAL REPAIR OF AORTIC COARCTATION

- At clinical examination, patient presents absent femoral and left arm pulses and 180/100 mmHg arterial pressure at right arm .
- MRI shows complete interruption of thoracic Aorta in a 9 mm. long segment , and marked development of collateral circulation .
- Endovascular treatment by percutaneous angioplasty with balloon-expandable PTFE covered Stent was proposed to restore Aortic continuity.

ENDOVASCULAR TREATMENT OF COMPLETE INTERRUPTION OF THORACIC AORTA POST SURGICAL REPAIR OF AORTIC COARCTATION

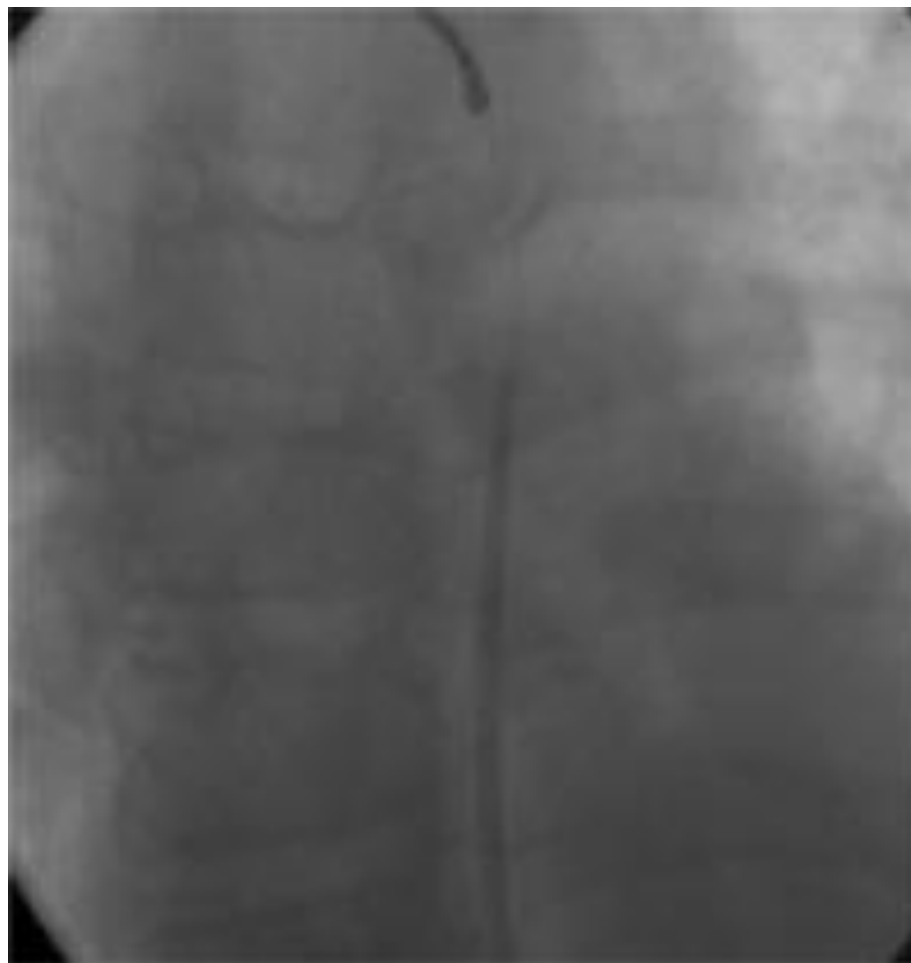- Catheterization was performed, under sedation and IV analgesia, by percutaneous right femoral and right braquial approach.
- Angiography shows complete interruption in a 9 mm long segment.

Radiofrequency perforation using a Nykanen™ RF 0.021" wire with a Bayliss™ RF generator was used to advance trough the scar tissue from femoral approach.



ENDOVASCULAR TREATMENT OF COMPLETE INTERRUPTION OF THORACIC AORTA POST SURGICAL REPAIR OF AORTIC COARCTATION

- Perforation was performed in 5 successive steps under fluoroscopic control in AP and LAT views, with small contrast tests through the braquial approach.
- Once it was done., the Nykanen wire was snared from the braquial approach, to give support to exchange the wire for a 0.035 stiff wire.

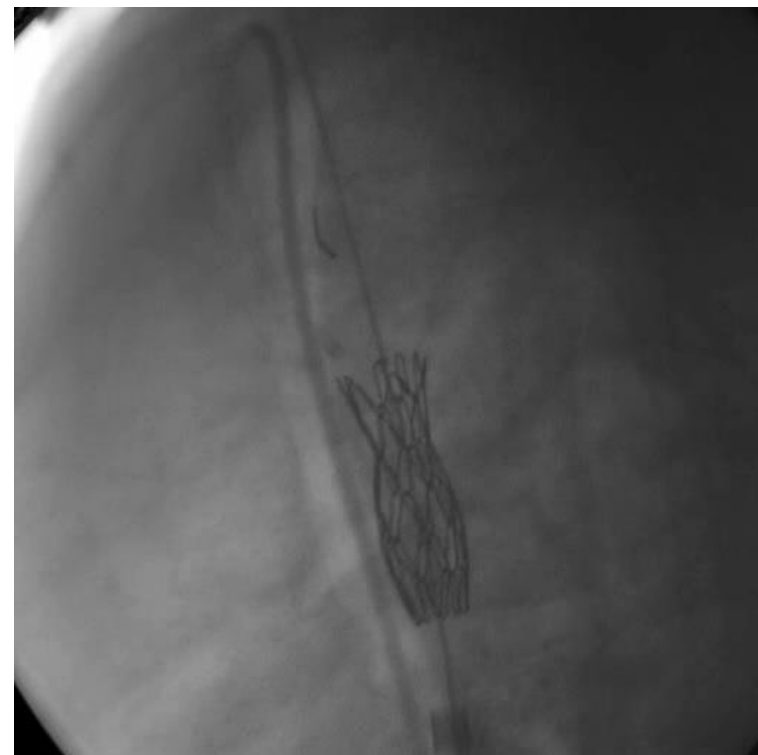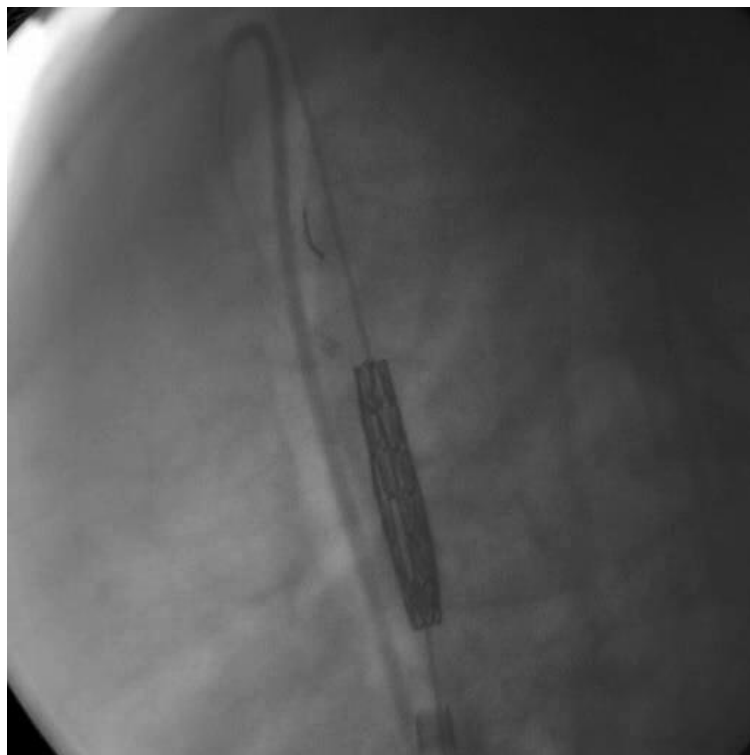


ENDOVASCULAR TREATMENT OF COMPLETE INTERRUPTION OF THORACIC AORTA POST SURGICAL REPAIR OF AORTIC COARCTATION

- Over the stiff wire, a 13F Mullins sheath was introduced across the scar tissue, without balloon predilation.
- A 8 zigs by 39 mm ,PTFE covered CP Stent™ (Numed), was mounted on a BIB™ (Numed) balloon, 45 mm long , with a 16 mm external balloon, and 8 mm internal balloon.
- The whole system was introduced over the wire, trough the Mullins sheath and positioned under fluoroscopic control.

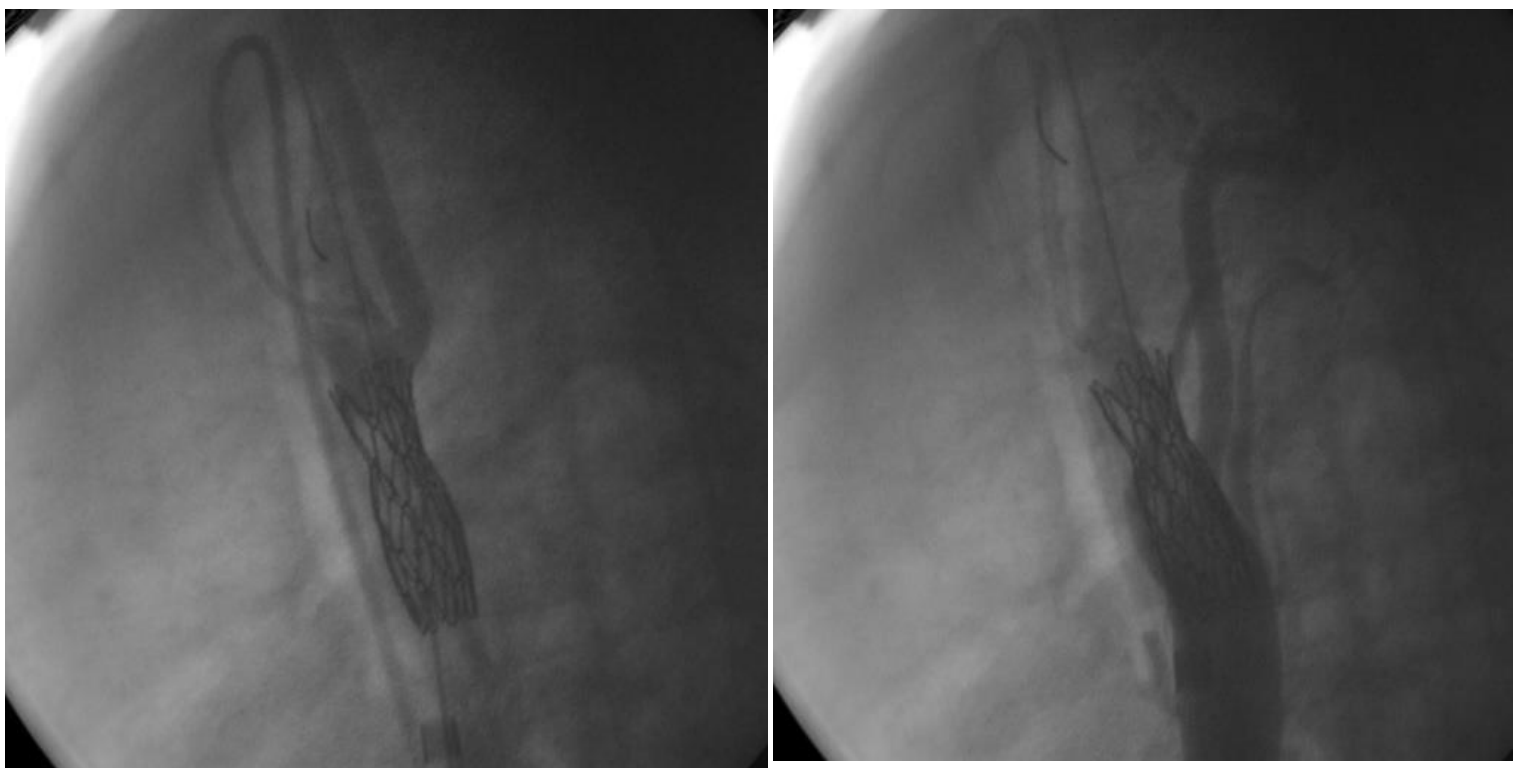
ENDOVASCULAR TREATMENT OF COMPLETE INTERRUPTION OF THORACIC AORTA POST SURGICAL REPAIR OF AORTIC COARCTATION

- Internal and external balloons were insufflated until nearly complete expansion was achieved at 6 psi.



ENDOVASCULAR TREATMENT OF COMPLETE INTERRUPTION OF THORACIC AORTA POST SURGICAL REPAIR OF AORTIC COARCTATION

- Final results show good flow through the stent graft in angiography and no residual gradient at the pressure measurements, so redilatation with high pressure balloon was no necessary.



ENDOVASCULAR TREATMENT OF COMPLETE INTERRUPTION OF THORACIC AORTA POST SURGICAL REPAIR OF AORTIC COARCTATION

- Patient remained 48hs. at ICU with uneventful recovery.
- Blood pressure measurements were in normal values.
- RMI and TEE showed good flow through the Stent and no evidence of dissection or hematoma.
- Femoral pulses were normal.
- At 72 hs was discharged without medication
- At 1 year follow-up remains normotensive on no medication.

ENDOVASCULAR TREATMENT OF COMPLETE INTERRUPTION OF THORACIC AORTA POST SURGICAL REPAIR OF AORTIC COARCTATION

- **Conclusion**
- Endovascular treatment of acquired complete interruption of thoracic aorta was feasible, using radiofrequency perforation of the atretic segment and restoration of aortic continuity by means of balloon expandable PTFE covered **C**heetham **P**latinum **S**tent and **B**alloon-**I**n-**B**alloon, angioplasty.