

IMAGES

in PAEDIATRIC CARDIOLOGY

Boehm W, Emmel M, Sreeram N. Balloon Atrial Septostomy: History and Technique. *Images Paediatr Cardiol* 2006;26:8-14

University Hospital of Cologne, Germany.

MeSH

Transposition of the great arteries Heart defects, congenital Catheter, intervention
Balloon atrial septostomy

Introduction

"A technique for producing an atrial septal defect without thoracotomy or anesthesia is presented. It can be performed rapidly in any cardiac catheterization laboratory." (William J. Rashkind, 1966)¹

"...The initial response to this report varied between admiration and horror but, in either case, the procedure stirred the imagination of the "invasive" cardiologists throughout the entire cardiology world and set the stage for all future intracardiac interventional procedures – the true beginning of pediatric and adult interventional cardiology." (Charles E. Mullins, 1998)²

The natural history of untreated transposition of the great vessels in the neonate is poor. Complete correction has been possible since 1959 with the atrial switch procedure, first described by Senning.³ Mustard simplified this method, reducing mortality rates to a reasonable level.⁴ Best results with both operations were achieved in children beyond six months of age. Therefore an early palliation by creation of an intraatrial communication was imperative. A surgical technique widely practised was described by Blalock and Hanlon in 1950.⁵ In 1966 Rashkind and Miller described a nonsurgical procedure to create an atrial septal defect, using a balloon catheter.¹ Since then it has remained an integral part of cardiac catheterisation in neonates, even after the introduction of the arterial switch procedure by Jatene and associates in 1976.⁶ Balloon atrial septostomy could be of potential benefit in patients with other severe congenital heart defects, such as tricuspid or mitral atresia, or total anomalous pulmonary venous drainage, with a restrictive foramen ovale. The use of two-dimensional transthoracic echocardiography to monitor the procedure,⁷⁻⁹ and the possibility of using the umbilical vein as an access site¹⁰ have simplified this procedure dramatically, so that it can be performed at the bedside in the neonatal intensive care unit.^{11,12} Used primarily in newborn children under six weeks of age, balloon atrial septostomy has limitations in older infants, due to the increased thickness of the atrial septum. In these cases blade septostomy and static balloon dilation of the atrial septum are preferred to enlarge the interatrial communication. These techniques are however outside the scope of this paper.

Catheter description

A variety of catheters are in use for balloon atrial septostomy. The most commonly used catheter at the present time, the 5F Miller balloon atrial septostomy catheter (Edwards Lifesciences, Irvine, CA, USA), needs an 7F to 8F introducer. The low profile, dual lumen Z-5 atrioseptostomy catheter¹³ (Numed, Cornwall, ON, Canada), comes in 4F or 5F sizes, depending on the balloon diameter, and requires a 5 or 6F introducer, respectively. The Z-5 catheter is advanced over a guidewire, as opposed to the Miller catheter.

Technique

The procedure can be performed under sedation or general anaesthesia. The access can be achieved via the femoral or the umbilical vein. The femoral vein is punctured in the typical way, an 4 or 5F introducer is placed in the vessel, and then exchanged for a 7F or 8F introducer, when the Miller catheter is used. The balloon catheter is advanced into the right atrium. Then the foramen ovale is crossed and the catheter is positioned in the left atrium. Correct position is documented via biplane fluoroscopy or two-dimensional echocardiography. In the anteroposterior fluoroscopic projection, it is sometimes advantageous to position the catheter tip in the orifice of the left upper pulmonary vein (outside the cardiac silhouette), to confirm its left atrial location (figures 1 and 2).

Figure 1: Frontal radiographic projection: The tip of the Miller balloon catheter is in the orifice of the left upper pulmonary vein (translucent arrow). The location of the introducer sheath in the abdominal IVC is also shown (black arrow).

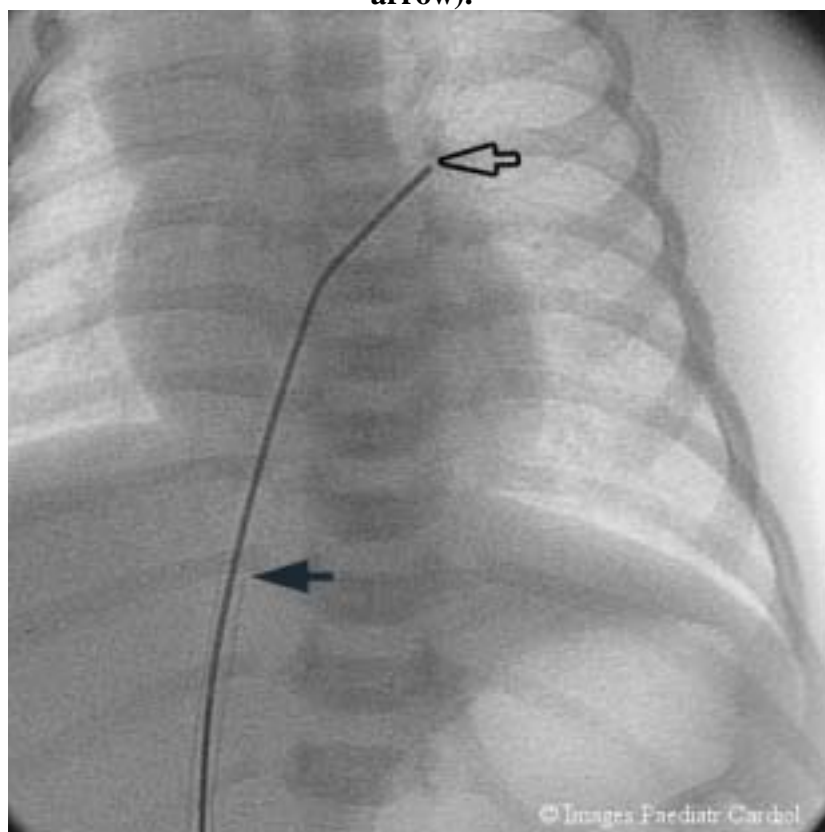
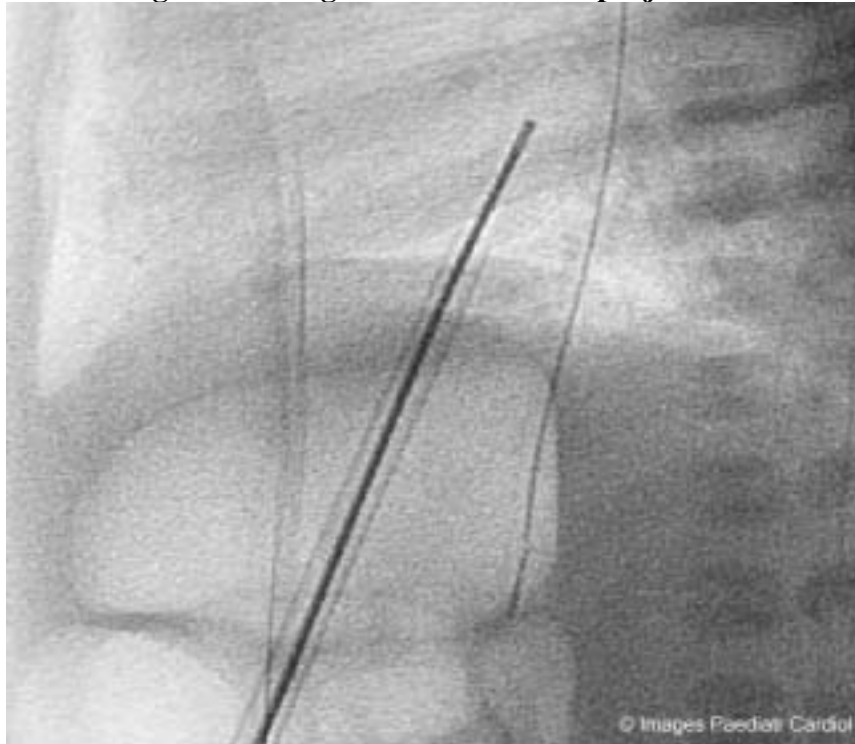


Figure 2: As figure 1 in the lateral projection.



The balloon is quickly inflated with 3-4 ml of dilute radiopaque solution, locked, and then sharply withdrawn into the right atrium down to the junction of the inferior caval vein. The catheter is then advanced into the body of the right atrium, so as not to obstruct inferior caval return, and then deflated rapidly. This maneuver may be repeated two to three times. The size of the interatrial communication can be measured directly by echocardiography at the table. The efficacy is usually immediately obvious, from the rise in systemic arterial saturation (figures 3-5).

Figure 3: Balloon atrial septostomy under fluoroscopic guidance in the frontal projection

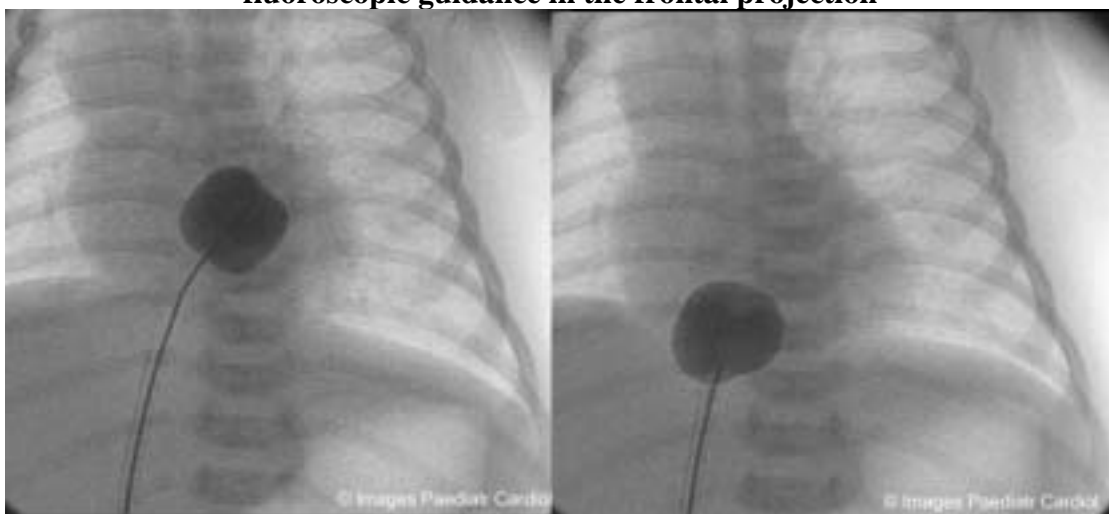


Figure 4: Balloon atrial septostomy under fluoroscopic guidance, lateral projection.

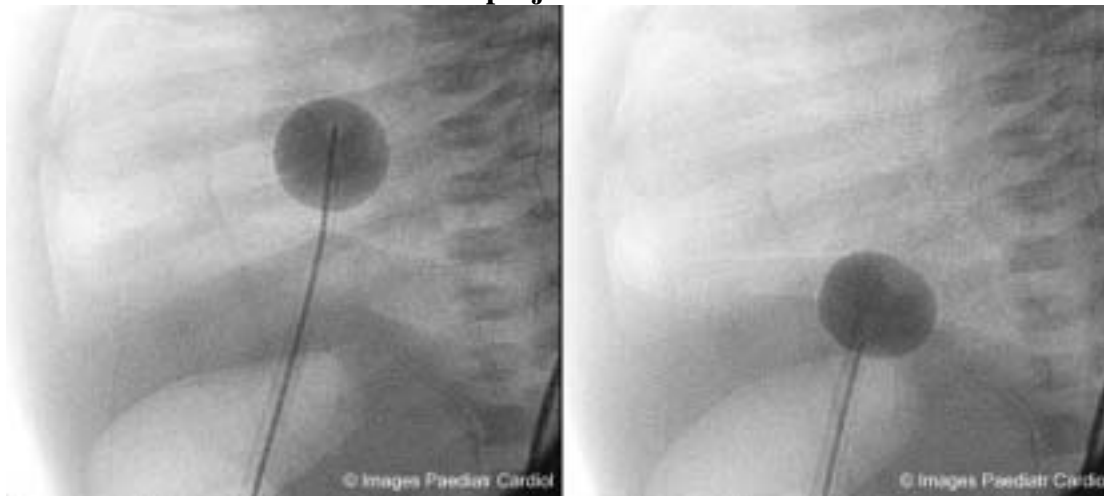
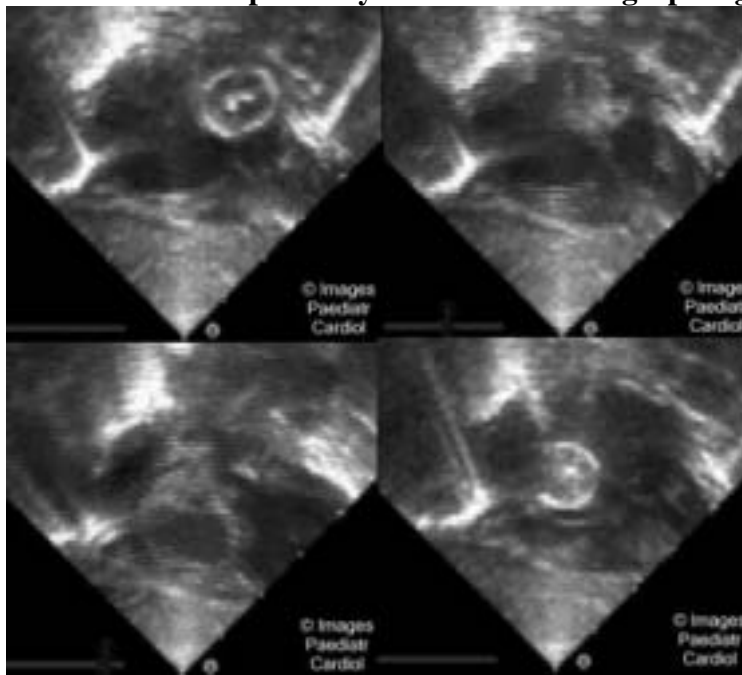


Figure 5: Balloon atrial septostomy under echocardiographic guidance.



Using the umbilical venous approach, the umbilical cord is cut transversely, flush with the skin, the vein is identified, and the catheter directly inserted into the vessel with the aid of a forceps. The progress of the catheter through the ductus venosus can be monitored either by fluroscopy (in which case the catheter passes from the right of the midline superiorly towards the right atrium in the anteroposterior projection, and from front to back in the lateral projection), or by cross sectional echocardiography. After reaching the right atrium, the procedure is done as described above. Sometimes it may be difficult to pass the catheter into the inferior vena cava due to stenosis or closure the ductus venosus. In this case an 0.018" guidewire and 4F endhole catheter combination can be introduced into the umbilical vein, and then manipulated into the right atrium. Thereafter, a standard 7F or 8F sheath can be used to introduce the septostomy catheter. When using a sheath in the umbilical vein, it must be borne in

mind that the tip of the sheath is often inside the right atrium, and may impede withdrawal of the inflated balloon across the septum. It is therefore important to remember to withdraw the sheath well into the ductus venosus prior to performing the septostomy. With the Z-5 atrioseptostomy catheter, it is easiest to position the guidewire (0.014" or 0.021") in the left upper pulmonary vein. The balloon catheter is advanced over the wire into the left atrium, and the septostomy carried out in a standard fashion.

Although it is a safe procedure, various complications have been reported, in upto 11% of procedures in some series.¹⁴⁻²⁵ These consist of rhythm disturbances (premature ectopic beats, supraventricular tachycardia, atrial flutter and fibrillation, partial or complete heart block, ventricular arrhythmias), perforation of the heart, balloon fragment embolization, laceration of atrioventricular valves, systemic or pulmonary veins and failure of balloon deflation. In practice, it is unusual to have a complication associated with the procedure at the present day.

Discussion

Generally agreed indications for balloon atrial septostomy are: transposition of the great arteries with or without associated cardiac defects (its role in patients with a large duct may be questionable, if the systemic saturation can be adequately maintained with prostaglandin E infusion alone, although in our experience the combination of a large atrial communication and a small duct [prostaglandin E infusion maintained at 5 nanograms/kg/min] appears to produce the most stable hemodynamics), tricuspid atresia with restrictive ASD, pulmonary atresia with intact ventricular septum and total anomalous pulmonary venous connection with restrictive ASD. It may be indicated in patients with hypoplastic left heart syndrome for emergency relief of the transseptal atrial gradient in neonates with a severely restrictive interatrial defect. Balloon atrial septostomy is an effective treatment in infants less than six weeks.²⁶⁻³⁰ It is inappropriate in children older than 1-2 months.

Summary

Although the arterial switch operation for transposition of the great vessels is typically performed within days after birth, and a left to right shunt through an open ductus arteriosus can be maintained with prostaglandine E, creation of an additional shunt at the atrial level is easy to achieve, provides stable arterial oxygen saturations and can therefore be routinely recommended.

References

1. Rashkind WJ, Miller WW. Creation of an atrial septal defect without thoracotomy. A Palliative Approach to Complete Transposition of the Great Arteries. *JAMA* 1966; 196: 991-2
2. Mullins CE. History of Pediatric Interventional catheterization: Pediatric Therapeutic Cardiac Catheterizations. *Pediatr Cardiol* 1998; 19: 3-7
3. Senning A. Surgical correction of transposition of the great vessels. *Surgery* 1959; 45: 966-80
4. Mustard WT. Successful two-stage correction of transposition of the great vessels. *Surgery* 1964; 55: 469-72
5. Blalock A, Hanlon CR. The surgical treatment of complete transposition of the aorta and the pulmonary artery. *Surg Gynecol Obstet* 1950; 90: 1-15

6. Jatene AD, Fontes VF, Paulista PP, Souza LCB, Neger F, Galantier M, Sousa JEMR. Anatomic correction of transposition of the great vessels. *J Thorac Cardiovasc Surg* 1976; 72: 364-70
7. Allan LD, Leanage R, Wainwright R, Joseph MC, Tynan M. Balloon atrial septostomy under two dimensional echocardiographic control. *Br Heart J* 1982; 47: 41-3
8. Perry LW, Ruckman RN, Galioto FM Jr, Shapiro SR, Potter BM, Scott LP. Echocardiographically assisted balloon atrial septostomy. *Pediatrics* 1982; 70: 403-8
9. Kipel G, Arnon R, Ritter SB. Transesophageal echocardiographic guidance of balloon atrial septostomy. *J Am Echocardiogr* 1991; 4: 631-5
10. Abinader E, Zeltzer M, Riss E. Transumbilical atrial septostomy in the newborn. *Am J Dis Child* 1970; 119: 354
11. Baker EJ, Allan LD, Tynan MJ, Jones OD, Joseph MC, Deverall PB. Balloon atrial septostomy in the neonatal intensive care unit. *Br Heart J* 1984; 51: 377-8
12. Zellers TM, Dixon K, Moake L, Wright J, Ramaciotti C. Bedside balloon atrial septostomy is safe, efficacious, and cost-effective compared with septostomy performed in the cardiac catheterization laboratory. *A J Cardiol* 2002; 89: 613-5
13. Hijazi Z, Geggel R, Aronovitz M, Marx G, Rhodes J, Fulton D. A new low profile balloon atrial septostomy catheter. Initial animal and clinical experience. *J Invas Cardiol* 1994; 6: 209-12
14. Venables AW. Balloon atrial septostomy in complete transposition of great arteries in infancy. *Br Heart J* 1970; 32: 61-5
15. Vogel JH. Balloon embolization during atrial septostomy. *Circulation* 1970; 42: 155-6
16. Parsons CG, Astley R, Burrows FG, Singh SP. Transposition of great arteries: a study of 65 infants followed for 1 to 4 years after balloon septostomy. *Br Heart J* 1971; 33: 725-31
17. Hohn AR, Webb HN. Balloon deflation failure: a hazard of "medical" atrial septostomy. *Am Heart J* 1972; 83: 389-91
18. Gutgesell HP, McNamara DG. Transposition of the great arteries: results of treatment with early palliation and late intracardiac repair. *Circulation* 1975; 51: 32-8
19. Blanchard WB, Knauf DG, Victorica BE. Interatrial groove tear: an unusual complication of balloon atrial septostomy. *Pediatr Cardiol* 1983; 4: 149-50
20. Ozkutlu S, Ozbarlas N. Successful treatment of a nondeflatable balloon atrial septostomy catheter. *Int J Cardiol* 1992; 34: 348-50
21. Caixeta AM, Kajita LJ, Rati M, Assis RV, Aiello V, Snitcowsky R, Perin MA, Veloso WU, Arie S. Ductus arteriosus rupture as a balloon catheter atrioseptostomy complication. *Cathet Cardiovasc Diagn* 1995; 34: 48-51
22. Akagi T, Tananari Y, Maeno YV, Himeno W, Furui J, Ishii M, Kato H. Torn-off balloon tip of Z-5 septostomy catheter. *Cathet Cardiovasc Intervent* 2001; 52: 500-3
23. Ellison RC, Plauth WH Jr, Gazzaniga AB, Fyler DC. Inability to deflate catheter balloon: a complication of balloon atrial septostomy. *J Pediatr* 1970; 76: 604-6
24. Scott O. A new complication of Rashkind balloon septostomy. *Arch Dis Child* 1970; 45: 716-7
25. William GD, Ahrend TR, Dungan WT. An unusual complication of balloon-catheter atrial septostomy. *Ann Thorac Surg* 1970; 10: 556-9

26. Rashkind WJ, Miller WW. Transposition of the great arteries: results of palliation by balloon atrioseptostomy in thirty-one infants. *Circulation* 1968; 38: 453-62
27. Singh SP, Astley R, Burrows FGO. Balloon septostomy for transposition of the great arteries. *Br Heart J* 1969; 31: 722-6
28. Baker F, Baker L, Zoltun R, Zuberbuhler JR. Effectiveness of the Rashkind procedure in transposition of the great arteries in infants. *Circulation* 1971; 5 (Suppl 1): I 1-6
29. Neches WH, Mullins CE, McNamara DG. The infant with transposition of the great arteries, II: results of balloon atrial septostomy. *Am J Heart* 1972; 84: 603-9
30. Wars CJ, Hawker RE, Cooper SG, Brieger D, Nunn G, Cartmill TB, Celermajer JM, Sholler GF. Minimally invasive management of transposition of the great arteries in the newborn period. *Am J Cardiol* 1992; 69: 1321-3

Contact information

[N. Sreeram](mailto:N.Sreeram)

Department of Paediatric Cardiology
University Hospital of Cologne

Kerpenerstrasse 62

50937 Cologne, Germany

Phone: +49 221 47886301

Fax: +49 221 47886302

N.Sreeram@uni-koeln.de

© Images in
Paediatric Cardiology
(1999-2005)

